

## FETAL ECHOCARDIOGRAPHY USING TRANSVAGINAL AND TRANSABDOMINAL PROBES DURING THE FIRST PERIOD OF PREGNANCY: A COMPARATIVE STUDY

RENZO D'AMELIO, CLAUDIO GIORLANDINO, LIANA MASALA, MASSIMO GAROFALO,  
MONICA MARTINELLI, GIUSEPPE ANELLI AND LUCIO ZICHELLA

*First Clinic of Obstetrics and Gynaecology, University of Rome 'La Sapienza', Rome, Italy*

### SUMMARY

The authors compare the diagnostic possibilities of fetal transabdominal echocardiography versus transvaginal echocardiography. A larger diagnostic capacity is verified in different gestation ages with transvaginal probe between the 11th and 14th week of gestation. The results are emphasized by colour Doppler.

**KEY WORDS** Fetal echocardiography Transvaginal probe Cardiac malformation

### INTRODUCTION

Fetal echocardiography holds a first-rate position in prenatal diagnosis: among all congenital malformations, cardiac defects occur very frequently (Allan *et al.*, 1982; Kleinman and Santulli, 1983; Kleinman *et al.*, 1980).

Some authors report that 9 out of 1000 newborn babies suffer from these pathologies. Of these, 45 per cent die within the first year of life (Hoffman and Christianson, 1978; Mitchell *et al.*, 1971). Today an exact and prompt prenatal diagnosis is more important than ever because of the possibility of intervening in fetuses with pharmacologic therapies and of providing correct timing of delivery and appropriate neonatal care.

The object of this research was to compare the resolution of transabdominal and transvaginal probes, the latter being recently introduced in echographic practice. The first aim was to assess whether it is possible to diagnose cardiac morphological alterations by the endovaginal probe at the earliest possible stage of pregnancy.

### MATERIALS AND METHODS

One hundred and sixty-two pregnant women, from the 11th to the 21st week of gestational age, were studied. They were between 25 and 23 years old and their medical histories were negative for cardiopathies and systemic pathologies (IUGR, diabetes, infections during pregnancy, more than 40 years old). Transvaginal and

---

Addressee for correspondence: Giorlandino Claudio, MD, Viale Liegi, 49, 00198 Rome, Italy.

0197-3851/91/020069-07\$05.00  
© 1991 by John Wiley & Sons, Ltd.

Received 27 February 1990  
Accepted 17 May 1990

Table 1. Cardiac structures analysed

Right atrium	RA
Right ventricle	RV
Left atrium	LA
Left ventricle	LV
Pulmonary valve	PV
Mitral valve	MV
Tricuspid valve	TV
Ascending aorta	AA
Interatrial septum	IAS
Interventricular septum	IVS
Aortic valve	AV

Table 2. Gestational age between 11th and 14th weeks

	Transvaginal probe						Transabdominal probe					
	B-Mode			Time-Motion			B-Mode			Time-Motion		
	2	1	0	2	1	0	2	1	0	2	1	0
LV	80	20	0	80	0	20	40	0	60	0	0	100
RV	80	20	0	80	20	0	20	20	60	0	0	100
RA	40	40	20	40	0	60	40	0	60	70	0	30
LA	40	40	20	40	20	40	0	40	60	0	20	80
IAS	40	20	40	40	20	40	20	0	80	0	0	100
IVS	80	0	20	80	0	20	0	40	60	0	0	100
AV	40	20	40	40	0	60	40	0	60	40	0	60
PV	40	0	60	0	0	100	0	40	60	0	0	100
MV	40	0	60	40	0	60	40	0	60	40	0	60
TV	40	0	60	40	0	60	40	0	60	0	0	100
AA	40	0	60	40	0	60	40	0	60	0	0	100

transabdominal echocardiographic observations were made. We used an Ansaldo 405/440/450 real time scanner with 3.5 MHz convex transabdominal and 5.0 MHz transvaginal probes.

Morphologic examination of the heart was carried out using both probes in the B-mode and real time.

The observations were performed by six different sonographers who were all equally expert in prenatal echocardiography, having more than 5 years' experience in transabdominal fetal echocardiography and more than 3 years' experience in transvaginal practice.

Patients were assigned randomly to the sonographers.

Eleven cardiac structures were examined (Table 1) and for each the operators were requested to choose one of the following possibilities: good visualization (2); fair visualization (1); bad or no visualization (0).

Table 3. Gestational age between 15th and 18th weeks

	Transvaginal probe						Transabdominal probe					
	B-Mode			Time-Motion			B-Mode			Time-Motion		
	2	1	0	2	1	0	2	1	0	2	1	0
LV	70	0	30	70	0	30	100	0	0	70	0	30
RV	70	0	30	70	0	30	100	0	0	70	0	30
RA	30	0	70	30	0	70	30	0	70	60	0	40
LA	30	0	70	30	0	70	70	0	30	40	0	60
IAS	30	30	40	70	0	30	60	0	40	30	0	70
IVS	70	0	30	70	0	30	100	0	0	70	0	30
AV	70	0	30	70	0	30	100	0	0	80	0	20
PV	100	0	0	100	0	0	100	0	0	80	0	20
MV	70	0	30	70	0	30	100	0	0	70	0	30
TV	70	0	30	70	0	30	100	0	0	70	10	20
AA	70	0	30	70	0	30	100	0	0	70	0	30

Table 4. Gestational age between 19th and 21st weeks

	Transvaginal probe						Transabdominal probe					
	B-Mode			Time-Motion			B-Mode			Time-Motion		
	2	1	0	2	1	0	2	1	0	2	1	0
LV	0	0	100	0	0	100	100	0	0	100	0	0
RV	0	0	100	0	0	100	100	0	0	100	0	0
RA	0	0	100	0	0	100	100	0	0	100	0	0
LA	0	0	100	0	0	100	100	0	0	100	0	0
IAS	0	0	100	0	0	100	80	20	0	60	10	30
IVS	0	0	100	0	0	100	100	0	0	100	0	0
AV	0	0	100	0	0	100	100	0	0	100	0	0
PV	0	0	100	0	0	100	70	30	0	70	0	30
MV	0	0	100	0	0	100	100	0	0	100	0	0
TV	0	0	100	0	0	100	100	0	0	100	0	0
AA	0	0	100	0	0	100	100	0	0	100	0	0

The percentage of visualization was approximated to the nearest decimal point and the women were divided into three smaller groups:

- (1) gestational age between the 11th and 14th week [57 subjects (Table 2)];
- (2) gestational age between the 15th and 18th week [69 subjects (Table 3)]; and
- (3) gestational age between the 19th and 21st week [36 subjects (Table 4)].

The agreement was generally good and for the transvaginal examination a maximum of 5 min of observation was allowed.

All the observed cases were followed during the entire pregnancy until delivery or termination of pregnancy and each newborn child was examined carefully.

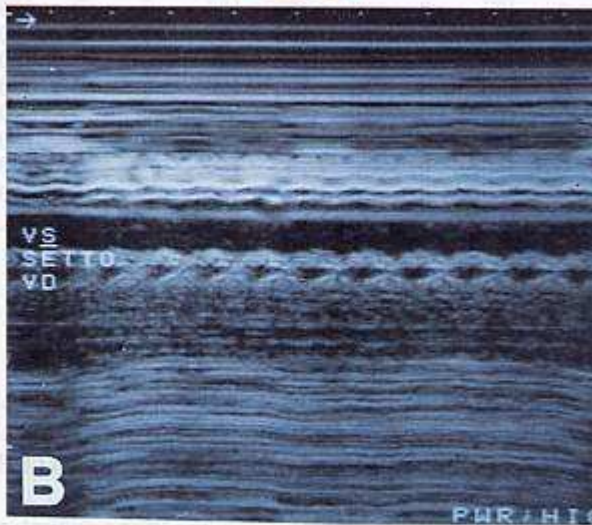
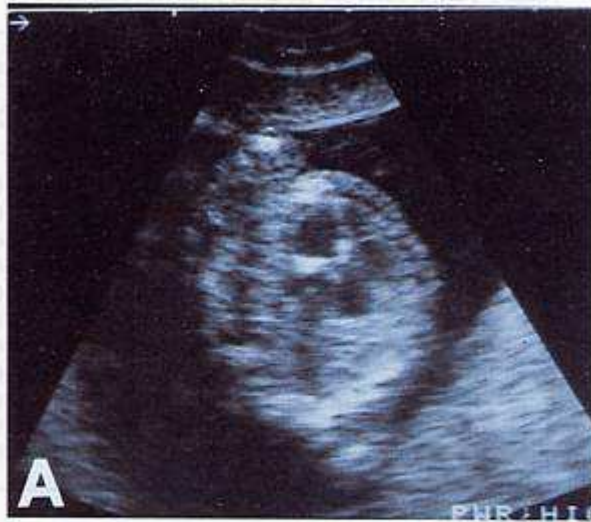


Figure 1. (A) Transvaginal echocardiography of a 14-week gestational age fetus. LV = Hypertrophic left ventricle with mitralic valve and septal anomalies. (B) Same scan in time motion mode

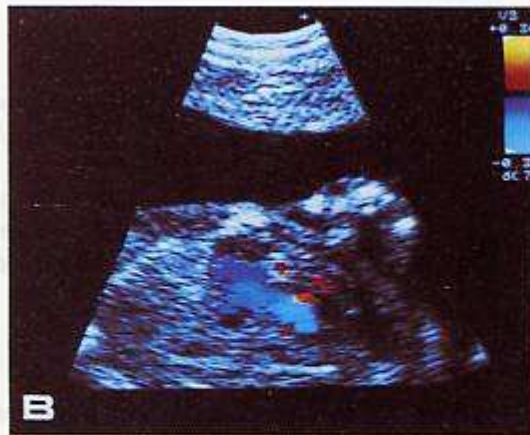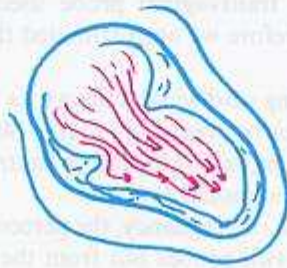

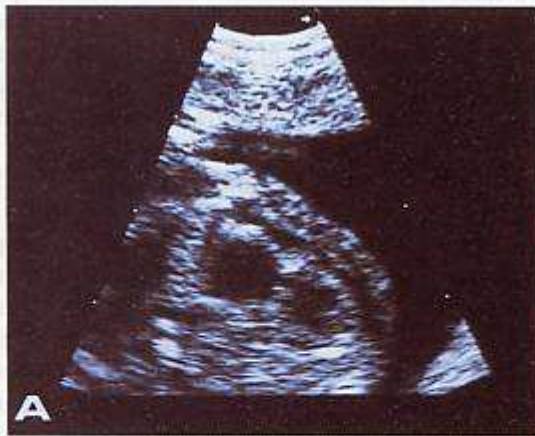
Figure 2. (A) Transvaginal echocardiography of a 15-week gestational age fetus showing just one atrium and a single large ventricle divided by a valve (univentricular heart). (B) Same picture in colour Doppler mode

## RESULTS

The best visualization of the cardiac structures during the very early weeks of pregnancy was obtained with a transvaginal probe. By this method the highest resolution occurred between the 11th and 14th week (Table 2).

At this stage, two cases of cardiac anomalies were detected by the transvaginal probe. The first case showed an alteration of the mitral valve and septum with ventricular asymmetry at the beginning of the 14th week (Figure 1). The parents requested termination of pregnancy and the post-mortem diagnosis was as follows: atresia of the aorta and hypertrophy of the mitral valve and of the interventricular septum.

The results obtained between the 15th and 18th week (Table 3) show that the transabdominal and transvaginal probes offer equal advantages.

The sonographers came to believe that the best observation period using the transvaginal probe was around the 15th week. At this stage, another diagnosis of a cardiac anomaly was made using colour Doppler with the transvaginal probe. The diagnosis was a univentricular heart with hydropericardium (Figure 2). An amniocentesis was performed and it revealed the presence of Down's syndrome.

Termination of pregnancy was requested and the post-mortem examination confirmed the diagnosis.

After the 19th week the transvaginal probe used was only occasional and visualization was poor. Therefore we approximated the results as 100 per cent of no visualization (Table 4).

The possibility of identifying cardiac structures by a transvaginal probe certainly gave better results in very early pregnancy (11th–14th week), especially for the visualization of the left atrium, left ventricle, interatrial septum, interventricular septum, tricuspid valve, and pulmonary valve.

Around the 15th–18th week of pregnancy, the percentage of correct visualization is almost the same with the two probes but from the 19th week transabdominal echography gives better results.

## DISCUSSION

Prenatal diagnosis has two objectives: correct diagnosis and speedy diagnosis. We believe that in fetal echocardiography, the transvaginal probe can be used successfully for the early diagnosis of cardiac anomalies.

We suggest the study of fetal cardiac anatomy with an endovaginal probe for cases at risk. Our data confirm that a transvaginal probe is more reliable than a transabdominal one in the period between the 11th and 18th week, giving best diagnostic results between the 14th and 15th week.

## REFERENCES

- Allan, L.D., Joseph, M.C., Boyd, E.G.C.A. *et al.* (1982). M-Mode echocardiography in the developing human fetus. *Br. Heart J.*, **47**, 573.
- Hoffman, J.I., Christianson, R. (1978). Congenital heart disease in a cohort of 19,502 births with long-term follow-up. *Am. J. Cardiol.*, **42**, 641.
- Kleinman, C.S., Santulli, T.V. (1983). Ultrasonic evaluation of the fetal human heart. *Semin. Perinatol.*, **7**, 90.

- Kleinman, C.S., Hobbins, J.C., Jaffe, C.C., *et al.* (1980). Echocardiographic studies of the human fetus: prenatal diagnosis of congenital heart disease and cardiac dysrhythmias. *Pediatrics*, **65**, 1059.
- Mitchell, S.C., Korones, S.B., Berendes, H.W. (1971). Congenital heart disease in 56,109 births. Incidence and natural history. *Circulation*, **43**, 323.